


PATIENT

Zoey Taggart

PRESENTING CLINICAL SIGNS

History: Suspected CHF. Grade 4 murmur, dyspnea, reduced appetite for 5 days. Currently on furosemide 10mg q18-12 hours, pimobendan 2.5mg q 12 (both started Sept 1).
 Abnormal PE/Chem/CBC/UA Results: Lymphopenia, hyperglycemia, incr ALT, ALP, low amyl

SPECIES

Canine

ECHOCARDIOGRAM FINDINGS

2D, m-mode, color flow and doppler imaging is available. Diffuse thickening of mitral valve leaflets with prolapse into the left atrial lumen. Severe eccentric mitral regurgitation with severe left atrial dilation. Normal MR velocity. Mild LV dilation with hyperdynamic myocardial function. The tricuspid valve appears normal, with mild TR. Normal velocity. Normal right atrial and ventricular diameter and morphology. The pulmonic and aortic valves are normal in morphology and mobility. Normal aortic and pulmonic outflow velocities with laminar flow. No AI/PI. No pericardial or pleural effusion noted. No obvious cardiac masses.

BREED

Swedish Vallhund

SEX

FS

AGE

11 years

WEIGHT

10kgs

CARDIAC CHART

CANINE CARDIAC PARAMETERS	MR VMAX (m/s)	TR VMAX (m/s)	LA/AO (Boon method)	LA/AO (Heart Base; Swe)	FS (%)	EF (%)	EPSS (cm)
NORMAL PARAMETER	4.5-5.5	<2.7	1.3	<1.6	28-40	40-100	<0.6
PATIENT	6.0	2.0	NM	2.2	49	82	NM
CANINE CARDIAC PARAMETERS	HR (BPM)	AV VMAX (m/s)	PV MAX (m/s)	BODY WEIGHT (kg)	LA (2D short axis Base view) (cm)	LVIDd (Avg; 2D and m-mode short axis) (cm)	LVIDs (Avg; 2D and m-mode short axis) (cm)
NORMAL PARAMETER	50-100	0.7-1.7	0.7-1.6	BELOW	BELOW	BELOW	BELOW
PATIENT	145	1.9	1.05	10	3.1	4.2	2.2
*Normal chamber parameters expressed as a mean value (SD)				3	1.27 (5.3)	2.46 (2.46)	1.36 (5.5)
BODY WEIGHT DEPENDENT PARAMETERS				5	1.40 (4.5)	2.74 (5.2)	1.60 (4.7)
<i>*Note: All measurements based upon multi-modal images and methods. An average value is reported.</i>				10	1.50 (3.8)	3.27 (3.5)	2.06 (3.1)
				15	1.83 (2.0)	3.71 (2.4)	2.43 (2.1)
				20	2.02 (1.9)	4.14 (2.2)	2.80 (2.0)
				25	2.18 (2.4)	4.48 (2.9)	3.10 (2.5)
				30	2.33 (3.3)	4.83 (3.9)	3.39 (3.4)
				35	2.48 (4.3)	5.17 (5.0)	3.69 (4.5)
				40	2.62 (5.2)	5.48 (6.1)	3.96 (5.4)
				50	2.88 (7.1)	6.07 (8.3)	4.46 (7.4)

INTERPRETED BY

 Maggie Machen Lamy,
 DVM DACVIM
 (Cardiology)

IMAGING PERFORMED BY

Kelly Reschny, CVT

HOSPITAL NAME

 Southside Animal
 Clinic

REFERRING VET

Dr. Delitara

INVOICE

20885

DATE

9/3/21

INTERPRETATION OF THE FINDINGS & FURTHER RECOMMENDATIONS

The cause of the murmur is chronic degenerative valve disease causing severe mitral and mild tricuspid regurgitation. Severe left atrial enlargement indicates the risk for spontaneous congestive heart failure is elevated. No additional issues are identified.



PATIENT

Zoey Taggart

SPECIES

Canine

BREED

Swedish Vallhund

SEX

FS

AGE

11 years

WEIGHT

10kgs

In light of the clinical signs, chest radiograph findings and severity of disease on echocardiogram, the diagnosis of congestive heart failure is supported (assuming the patient improved with Lasix therapy) and continued medications are warranted lifelong as below. Monitoring of sleeping respiratory rates will be paramount to screen for congestive heart failure at home. Cough suppression to improve QOL can also be considered (hydrocodone, 0.2-0.4mg/kg up to q4-6h PRN) for any residual mechanical cough in the face of normal sleeping respiratory rates. The average survival time of canine patients with active pulmonary edema is 8-9 months on medications, however they generally are able to maintain a good quality of life for that period. Patient will always be at risk for recurrent CHF, development of arrhythmias/LA tear, syncope and/or sudden death in the future.

Omega fatty acid supplementation and mild salt restriction may also be of some long term benefit. Monitor for acute progression of the cough, labored breathing, exercise intolerance or collapse episodes in the future.

Plan: Institute Pimobendan 0.3mg/kg PO q12h. Institute Furosemide 1-2mg/kg PO q12h. Institute spironolactone 1-2mg/kg PO q12h.

Monitor SRRs at home. Monitor renal values and BP in 10-14 days, then every 3-4 months while on diuretics. If doing well and BP >130mmHg, institute ACEI 0.5mg/kg PO q12h. Consider hydrocodone if needed for QOL.

Recommend conservative monitoring with a recheck echocardiogram in 6 months, sooner if any development of associated clinical signs occurs in the interim.

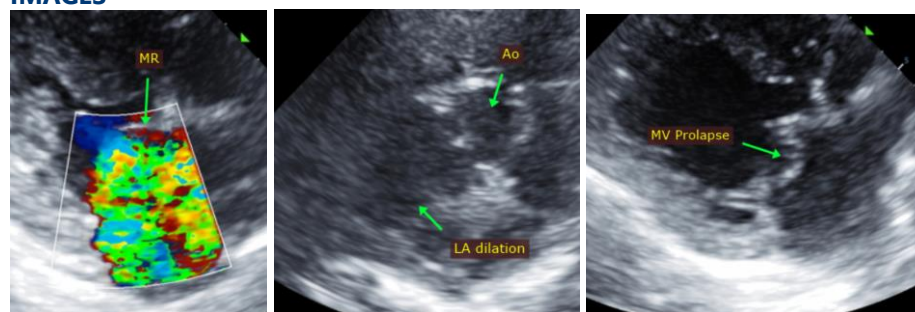
INTERPRETED BY

Maggie Machen Lamy,
DVM DACVIM
(Cardiology)

IMAGING PERFORMED BY

Kelly Reschny, CVT

IMAGES



HOSPITAL NAME

Southside Animal
Clinic

REFERRING VET

Dr. Delitara

The information and recommendations provided are based on the images presented by the referring veterinarian. No evaluation can be communicated regarding pathology that was not visible in the image/video clips provided.

Thank you for this referral. If the clinical or image interpretation does not parallel your findings or if I can be of any further assistance please contact me.

Maggie Machen Lamy, DVM

Diplomate of the American College of Veterinary Internal Medicine (Cardiology)
info@sonopath.com

INVOICE

20885

DATE

9/3/21